

Clinical signs and diagnosis of fibroids from adolescence to menopause

Eduard Mension, M.D., Ph.D.,^a Francisco Carmona, M.D., Ph.D.,^a Silvia Vannuccini, M.D., Ph.D.,^b and Charles Chapron, M.D., Ph.D.^c

^a Department of Obstetrics and Gynecology, Hospital Clínic of Barcelona, Spain, Institut d'Investigacions Biomèdiques August Pi i Sunyer (IDIBAPS), Facultat de Medicina, Universidad de Barcelona, Barcelona, Spain; ^b Obstetrics and Gynecology, Department of Experimental, Clinical and Biomedical Sciences, Careggi University Hospital, University of Florence, Florence, Italy; and ^c Département de Gynécologie, Obstétrique et Médecine de la Reproduction, AP-HP, Centre Hospitalier Universitaire (CHU) Cochin, Paris, France

The aim of this review was to provide an updated assessment of the present diagnostic tools and clinical symptoms and signs to evaluate uterine fibroids (UFs) on the basis of current guidelines, recent scientific evidence, and a PubMed and Google Scholar search for peer-reviewed original and review articles related to clinical signs and diagnosis of UFs. Approximately 50%–75% of UFs are considered nonclinically relevant. When present, the most common symptoms are abnormal uterine bleeding, pelvic pain and/or bulk symptoms, and reproductive failure. Transvaginal ultrasound is recommended as the initial diagnostic modality because of its accessibility and high sensitivity, although magnetic resonance imaging appears to be the most accurate diagnostic tool to date in certain cases. Other emerging techniques, such as saline infusion sonohysterography, elastography, and contrast-enhanced ultrasonography, may contribute to improving diagnostic accuracy in selected cases. Moreover, artificial intelligence has begun to demonstrate its ability as a complementary tool to improve the efficiency of UF diagnosis. Therefore, it is critical to standardize descriptions of transvaginal ultrasound images according to updated classifications and to individualize the use of the different complementary diagnostic tools available to achieve precise uterine mapping that can lead to targeted therapeutic approaches according to the clinical context of each patient. (Fertil Steril® 2024;122:12–9. ©2024 by American Society for Reproductive Medicine.)

Key Words: Uterine fibroids, leiomyomas, diagnosis, personalized

During the last few years, important advances in the pathophysiology of uterine fibroids (UFs) have been made, revealing potential new diagnostic and therapeutic approaches that may provide a paradigmatic change in the management of this disease.

Traditionally, UFs have been associated with classical risk factors, such as race, aging, and obesity, but it has been suggested that uterine stem cells of all women may have an intrinsic risk for the development of UFs, which can be increased by several “hits” to the hormonal stem cell pathways along their lifetime (1–4). Therefore, UFs

may be presented throughout the lifetime of a woman, being more frequent during the reproductive age from adolescence to menopause when hormonal inputs are greater (5). Nonetheless, many women presenting UFs do not present clinical symptoms or signs, with 50%–75% of UFs being considered as nonclinically relevant (2, 6, 7).

According to the literature, the incidence of UFs among the population is variable, ranging from 5.4%–77% in women of reproductive age. The upper limit of the incidence of UFs seems to be at around 50 years of age, with women at this age presenting a 10-

fold increased risk of developing UFs compared with those in their 30s. However, this increased risk disappears after the age of 60 (5), because UFs are responsive to estrogens and progestins, and thus, when menopause occurs, UF-associated symptoms may spontaneously resolve and cease (8, 9). The aim of this review was to provide an updated overview of the clinical symptoms to evaluate UFs and the current diagnostic tools available.

CLINICAL SYMPTOMS OF UFs

The most common symptoms of the presence of UFs are heavy menstrual bleeding or abnormal uterine bleeding (AUB), pelvic pain and/or bulk symptoms, and reproductive failure.

Abnormal uterine bleeding

Although the association between AUB and UFs has been reported, its pathophysiological mechanisms are not yet

Received May 1, 2024; accepted May 1, 2024; published online May 9, 2024.

Correspondence: Francisco Carmona, M.D., Ph.D., Department of Obstetrics and Gynecology, Hospital Clínic of Barcelona, Universidad de Barcelona, Villarroel 170, Barcelona 08036, Spain (E-mail: fcarmona@clinic.cat).

Fertil Steril® Vol. 122, No. 1, July 2024 0015-0282

Copyright ©2024 The Authors. Published by Elsevier Inc. on behalf of the American Society for Reproductive Medicine. This is an open access article under the CC BY-NC-ND license (<http://creativecommons.org/licenses/by-nc-nd/4.0/>).

<https://doi.org/10.1016/j.fertnstert.2024.05.003>

clearly established because many women with UFs may present entirely normal bleeding patterns. Once bleeding is defined as abnormal, the well-known acronym PALM-COEIN (polyp, adenomyosis, leiomyoma, malignancy, and hyperplasia; coagulopathy, ovulatory disorders, endometrial, iatrogenic, and not otherwise classified) is usually used for categorizing causes (10).

When AUB is present, in 45.7% of the cases, there is an UF associated with bleeding (11). However, when UF is diagnosed, it does not exclude the presence of other causes of AUB that may coexist with UF, such as adenomyosis, and thus its presence should be assessed (12). In addition, hormonal dysfunction in the premenopausal period may represent a confounding factor in the diagnosis of AUB associated with UFs (13, 14).

Regarding the location of UFs, it has been thought that women with submucosal fibroids, particularly those distorting the uterine cavity, were more likely to present AUB (15). However, there is current debate assessing the main possible causes provoking AUB, apart from the location itself. One of the main theories explaining the cause of AUB in patients presenting UFs seems to be the presence of increased microscopic myometrial venous dilatations in the uterine tissue surrounding UFs. These dilatations are produced by increased production of vascular endothelial growth factor, epidermal growth factor, and platelet-derived growth factor in the microenvironment, inducing increased angiogenesis, endometrial decidualization, and reduced hemostasis. Moreover, abnormal myometrial contractions have been related to induced AUB through a cascade of cytokines in the extracellular matrix cells surrounding UFs.

Finally, in many cases, AUB may lead to chronic iron deficiency and chronic anemia, although the women may be asymptomatic because of the chronic nature of this condition (13, 16–19).

Pain and bulk symptoms

Other symptoms related to UFs include complaints of chronic pelvic pain, dysmenorrhea, premenstrual pelvic pain, intercourse pain, and bladder pressure. However, an interesting international survey showed that women diagnosed with UFs compared with women without UFs significantly more often reported pain symptoms such as pressure on the bladder (32.6% vs. 15.0%), chronic pelvic pain (14.5% vs. 2.9%), painful sexual intercourse (23.5% vs. 9.1%), and pain occurring midcycle, after, and during menstrual bleeding (31.3%, 16.7%, 59.7%, vs. 17.1%, 6.4%, 52.0%) (20). Although these are common symptoms, their correlation with the size, number, or position of UFs has yet to be clearly established (21), and some investigators suggest that the characteristics of UFs may not correlate with bulk symptoms (22).

Reproductive failure

Reproductive failure is another clinical sign related to the presence of UFs. Some mechanisms of association between fibroids and infertility have been proposed, and epidemiological studies have shown that women with infertility had a 2.18 higher incidence of UFs (23).

Fibroid-related infertility may be caused by several mechanisms, such as uterine cavity deformation, impaired endometrial-myometrial blood supply, disturbed uterine contractility, hormonal, paracrine, and molecular changes, and impaired endometrial receptivity and gene expression. All these mechanisms were reviewed by Donnez et al. (4) in the same series of Views and reviews (24). The disruption of physiological myometrial contractility may interfere with both spermatozoa progression and embryo implantation (25), and moreover, UFs may alter the pelvic anatomy and impair the function of the fallopian tubes (26, 27). On the other hand, serosal UFs that have no impact on the uterine cavity do not seem to be related to reproductive failure or affect invitro fertilization treatment results (28, 29).

Fibroids during pregnancy

In relation to how UFs may change during pregnancy, some imaging studies have shown an increase in leiomyoma volume at any time during pregnancy, but others have noted size reduction or no change (30, 31). In addition, in late pregnancy and puerperium, the tendency is for volume reduction (32). The growth of UFs during pregnancy may occur mainly in the first seven gestational weeks because of increased estrogen levels and also human chorionic gonadotropin, angiogenic, and growth factors. The growth of UFs has a nonlinear trend in pregnancy, with a median change in volume up to 140% in early gestation. Conversely, in the postpartum, sustained ischemia and apoptosis promoted by uterine remodeling during its involution contribute to the shrinkage of UFs (33).

DIAGNOSTIC TOOLS AND CLASSIFICATION OF UTERINE FIBROIDS

Transvaginal ultrasound

When clinical symptoms or signs suggest the possible presence of UFs, the first line diagnostic technique that should be performed is transvaginal ultrasound (TVUS) because of its accessibility and low cost (10), as well as its high sensitivity and specificity comparable to magnetic resonance imaging (MRI) (34), offering the possibility of a precise mapped description of the UFs present in the uterus (35). A comparison of UF detection accuracy between TVUS and MRI (36) is reported in Table 1.

Uterine fibroids affecting the junctional zone (JZ) seem to present fewer cytogenetic abnormalities, a different pattern of

TABLE 1

Comparison of uterine fibroid detection accuracy between transvaginal ultrasound (TVUS) and magnetic resonance imaging (MRI).

	TVUS	MRI
Sensitivity (%)	99 (92–100)	99 (92–100)
Specificity (%)	91 (75–98)	86 (71–94)
Positive predictive value (%)	96 (88–99)	92 (93–97)
Negative predictive value (%)	97 (82–100)	97 (85–100)

Mension. Personalized diagnosis of UFs. Fertil Steril 2024.

vascularization, be more responsive to gonadotropin-releasing hormone analogues, and have fewer recurrences after surgery (17). Thus, an adequate description of the presence of JZ involvement is essential because it may influence symptoms and their response to treatments. In addition, different patterns and scores of myometrial vascularization provide important information regarding the growth of UFs (37, 38). The high diagnostic accuracy of these factors contributes to helping clinicians select better-targeted treatments or the clinical management of patients according to their different myometrium involvement and vascularization.

Furthermore, an adequate description of the inner myometrium (corresponding to the JZ), the middle myometrium (extending from the JZ to the venous and arterial arcuate vessels of the uterus), and the outer myometrium (located between the arcuate vessels and the uterine serosa) helps to achieve precise uterine mapping of the location of UFs. The vascular arcuate, observed in the sagittal plane in two-dimensional TVUS with the application of color or power Doppler, serves as a reference for the differentiation of uterine layers, which have been correlated with the presence of different symptoms (39). An example of uterine vascular arcuate is visible in Figure 1.

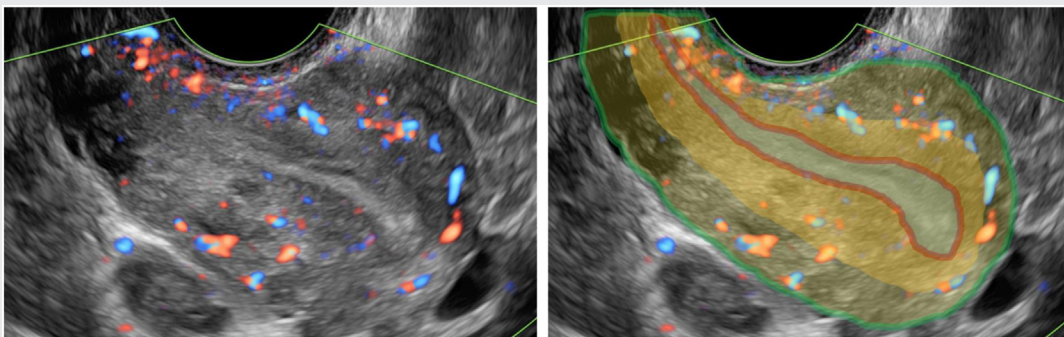
The Morphological Uterus Sonographic Assessment group description reports the sonographic features of the myometrium using gray-scale sonography, color/power Doppler, and three-dimensional ultrasound imaging, highlighting important characteristics of UFs, such as number, size, localization, echogenicity, acoustic shadow, vascularization, fibroid type, minimal distance to the serosa, and minimal distance to the mucosa. On the other hand, specific classifications of submucosal UF, such as the size, topography, extension, penetration, and wall, and the Lasmar classification, provide information on the expected difficulty and complexity of hysteroscopic UF resection according to the size, topography, extension, penetration, and wall of submucosal UFs (40). The Lasmar score is usually obtained by

diagnostic hysteroscopy, despite some investigators suggesting that TVUS may be able to provide the score when performed in the luteal phase of the menstrual cycle, avoiding office hysteroscopy without a loss of diagnostic accuracy (41). International validation of this classification for predicting hysteroscopic UF removal among a total population of 465 women showed that size, topography, extension, penetration, and wall ≤ 4 presented 100% of UF hysteroscopic resection success, although successful resection was achieved in 77.2% of women with a score >4 (42).

Furthermore, when UFs present an atypical appearance on TVUS, a differential diagnosis between UFs, uterine smooth muscle tumors of uncertain malignant potential (STUMP), and leiomyosarcomas is necessary. No specific characteristics of TVUS have proven to be effective for differentiating “typical myoma” from “STUMP” and leiomyosarcomas because of the lack of large series describing TVUS characteristics of diagnosed leiomyosarcomas. Nonetheless, some investigators have attempted to identify and define atypical signs using TVUS that might be suspicious of an atypical UF with a possible increased risk of finally becoming a STUMP or a leiomyosarcoma (43).

Typical UFs may present changes in morphology in response to different triggers. When UFs grow, the vascularization might be compromised, presenting, in some cases, partial necrosis classified as different kinds of pathologic degeneration (hyaline, myxoid, cystic, red, or dystrophic degeneration). Initially, these degenerations are difficult to detect using TVUS, with the only sign being a hyperechoic border without detection of power Doppler flow in the UF core. It is only in the late phase of internal UF necrosis that the resulting edema might present as a mixed echogenicity with hypoechoic cystic areas inside the UF (44, 45). These hypoechoic internal cystic areas with increased core vascularization, visualized using power Doppler as large UF-like uterine masses, can be suggestive of malignant myometrial tumors (46, 47).

FIGURE 1



Uterine vascular arcuate observed in the sagittal plane in two-dimensional transvaginal ultrasound with the application of color or power Doppler and description of the endometrium (blue), inner myometrium/junctional zone (red), the middle myometrium (orange: extending from the junctional zone (JZ) to the venous and arterial arcuate vessels of the uterus), the outer myometrium (yellow: located between the arcuate vessels and the uterine serosa), and uterine serosa (green).

Mension. Personalized diagnosis of UFs. Fertil Steril 2024.

Magnetic resonance imaging

Magnetic resonance imaging is the other remarkable imaging technique to assess UFs, presenting a high sensitivity and specificity (Table 1) and according to some investigators, is the most accurate diagnostic test to assess UFs (43). Notwithstanding, in cases of women presenting large UFs or a uterus that rises out of the pelvis, some investigators showed up to 36% discrepancies between clinicians in the classification of these cases when assessing UFs using TVUS, thus concluding that MRI appears to be superior to TVUS when assessing >4 fibroids or a uterus >375 cm³ (48). Moreover, MRI is a helpful complementary imaging technique to TVUS when assessing women presenting coexisting endometriosis and adenomyosis (36). Magnetic resonance imaging allows differentiation between UF and adenomyosis despite both appearing as hypointense lesions on T2-weighted images because adenomyosis usually shows poorly defined margins and an irregular shape, contrary to UFs. However, some studies have demonstrated that two-dimensional TVUS has a similar sensitivity and specificity for the diagnosis of adenomyosis compared with MRI (49). Table 2 shows the comparison of the advantages and disadvantages of TVUS and MRI as tools for the diagnosis of UFs.

Despite the better reproducibility of MRI, its interpretation might be more difficult than TVUS images. When degeneration is seen using TVUS, it is usually visualized as hypochoic internal cysts and calcifications. However, when assessed using MRI, different patterns of signal intensity are seen depending on the pathologic degeneration subtype. T2-weighted images may show hypointensity in typical UFs to marked hyperintensity in cystic degenerated UFs and hypercellular fibroids, although many cases may present isohypointensity in T1-weighted images (43).

Nonetheless, the differential diagnosis between UFs and uterine sarcoma is another indication for the use of MRI to assess uterine masses. According to a recent meta-analysis, MRI seems to be superior to TVUS in differentiating UFs from uterine sarcomas, presenting a sensitivity of 90% and a specificity of 96%, with a pooled accuracy of 97% (50), although TVUS has a sensitivity and specificity of 76% and 89%, respectively (51). Some of the image characteristics

associated with an increased risk of malignancy are the absence of a clear myometrial origin, the lack of a normal endometrial stripe, intermediate signal intensity on T2-weighted images, T2-weighted signal heterogeneity, signs of intratumoral hemorrhage, heterogeneous contrast enhancement, hyperintensity on high-b-value diffusion-weighted images, and low apparent diffusion coefficient values (43).

Despite these possible associations, there is still a lack of consensus because of contradictory findings in different studies and the overlap of these associations between benign and malignant lesions (52). Nevertheless, key points are starting to flourish, as Sato et al. (53) reported that UF-like masses, seen as hypointense in diffusion-weighted imaging, should be considered benign with 100% sensitivity and 94% specificity.

Therefore, indications for MRI to evaluate UFs comprise these cases with uncertainty regarding the anatomical origin of the mass, in cases of the large uterus with the presence of multiple leiomyomas, in cases with clinical suspicion of coexistence of endometriosis or adenomyosis, and in cases in which atypical signs have been seen using TVUS to assess the risk of malignancy.

Other techniques

During the last decade, other complementary techniques have been tested, and others have been developed to provide help for precise uterus mapping in specific cases. Techniques such as hysteroscopy and saline infusion sonohysterography (SIS) may help in cases in which TVUS presents doubts about an intrauterine image and in planning submucosal UF surgical interventions. Hysteroscopy remains the gold standard tool for the detection of intrauterine abnormalities, but SIS is a highly sensitive and specific test for the diagnosis of uterine polyps, submucous myomas, and intrauterine anomalies, being comparable to hysteroscopy with a sensitivity of 88% (85%–90%) and specificity of 94% (93%–96%) (54, 55). Saline infusion sonohysterography provides intracavity images of submucosal UFs with a high level of accuracy and is less invasive than hysteroscopy (56), and some studies have suggested that SIS may avoid hysteroscopy in some cases (57–59). One of its main uses is the study of infertility because SIS

TABLE 2

Comparison of the advantages and disadvantages between transvaginal ultrasound (TVUS) and magnetic resonance imaging (MRI) as tools for the diagnosis of uterine fibroids (UFs).

	Advantages	Disadvantages
TVUS	High S and Sp Faster Lower cost Better accessibility	Efficacy decreases when uterus >375 mL and presenting >4 UFs Operator-dependent
MRI	High S and Sp Better efficacy when uterus volume >375 mL and presenting >4 UFs Not operator-dependent Reproducibility	Higher false findings rate compared with TVUS Increased cost Time consuming

S = sensitivity; Sp = specificity.

Mension. Personalized diagnosis of UFs. Fertil Steril 2024.

combines the features of hysteroscopy and TVUS and can simultaneously visualize tubal patency, the uterine cavity, and other pelvic pathologies.

Elastography is an ultrasound technique that measures the stiffness of uterine tissue on the basis of differences in elasticity in response to compression or vibration (60). Although it is still in the research stage, elastography is a promising tool and may have a role in the diagnosis of UFs because of its low cost and noninvasiveness. It has been mainly tested in the differential diagnosis with adenomyosis, observing that UFs and adenomyosis may have different elastographic characteristics with different color patterns, with UFs, in most cases, being darker than adjacent myometrium, compared with a brighter appearance in cases of adenomyosis (61, 62). Elastography has been also compared with MRI in the assessment of UFs, obtaining a Cohen's kappa of 1.0 with MRI (60). Furthermore, some studies have also suggested a role of elastography in the diagnosis of malignant uterine tumors, because these tumors are known to present increased stiffness because of biomechanical modifications in uterine tissue (63).

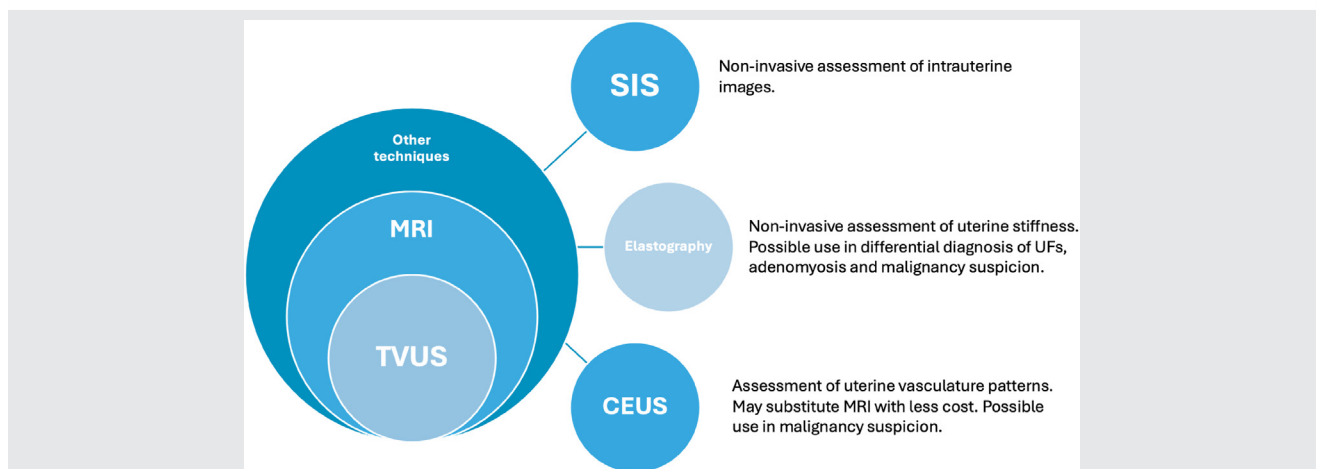
Moreover, contrast-enhanced ultrasound (CEUS) is a technique that uses endovenous gas-filled microbubbles with diameters $<8 \mu\text{m}$, and a lipid, protein, or polymer shell as ultrasound contrast agents to enhance the microvasculature of the myometrium (64). Thus, CEUS provides additional details compared with TVUS and SIS in terms of the pseudocapsule of fibroids, central necrosis, and intralesion vascularity patterns (65). Previous studies using CEUS have already assessed the normal behavior of UFs, showing that they tend to enhance earlier than the surrounding myometrium, and the peak of intensity differs depending on the degree of fibroid degeneration. Most fibroids (94.5%) present a more rapid ultrasound contrast agent wash-out than the surrounding myometrium (66). A recent systematic review reported a diagnostic accuracy for CEUS of 97.5% for intramural fibroids and 96.3% for other types (67), and some

investigators compare its high accuracy to MRI in uterine mass assessment, with a correlation of $R = 0.97$ ($P < .001$) (68). Despite its high accuracy, there is no data regarding uterine malignancies with CEUS. Nonetheless, CEUS may be a useful future tool because of its ability to better assess UF vascularization patterns than TVUS Doppler, and the visualization of microvessels seems to be helpful in differentiating UFs from malignant uterine tumors (67). Figure 2 shows the future diagnostic tools for the complete evaluation of UFs.

On the other hand, the use of older techniques, such as computed tomography, has been also assessed in the diagnosis of UFs, but do not seem to be useful for the assessment of UFs. However, incidental UFs are sometimes found on computed tomography, appearing as diffuse uterine enlargement or lobulated uterine contours demonstrating a density similar to that of normal uterine myometrium or in the form of uterine calcifications. Some investigators assessed the imaging of UFs using 18F-fluorodeoxyglucose positron emission tomography imaging, with UFs showing physiological 18F-fluorodeoxyglucose uptake in 10.4% of premenopausal and 1.2% of postmenopausal women, with maximum standard uptake values ranging between 3.0 and 10.0, and in degenerated UFs, standard uptake value may be higher compared with nondegenerated lesions (69).

Finally, artificial intelligence (AI) is currently being evaluated for different uses in the diagnosis of uterine alterations. For example, an AI-assisted method to assist junior ultrasonographers in improving the diagnosis of UFs was evaluated, with AI improving the results and being comparable to those of senior clinicians (70). Even more significantly, other investigators have used AI as a complementary diagnostic tool to existing three-dimensional TVUS images or for real-time automatic-assisted detection, presenting an average accuracy of 90%–95% for detecting UFs and achieving a detection speed of 0.28 seconds per image using deep learning-based algorithms, demonstrating that AI may be a helpful tool to

FIGURE 2



Future diagnostic tools for a complete evaluation of uterine fibroids (UFs). CESU = contrast-enhanced ultrasound; MRI = magnetic resonance imaging; SIS = saline infusion sonohysterography; TVUS = transvaginal ultrasound.

Mension. Personalized diagnosis of UFs. Fertil Steril 2024.

improve the efficiency of the diagnosis and follow-up of UFs, and may change the way UFs are diagnosed in the near future (71, 72).

CONCLUSIONS AND ESSENTIAL POINTS

UFs manifest throughout a woman's life, with increased frequency during the reproductive years, yet many cases remain asymptomatic. It is critical to be aware of the symptoms and signs that may lead to a possible diagnosis of the presence of UFs. When a UF is suspected, the first diagnostic tool chosen is TVUS for its high sensitivity and specificity, low cost, and good accessibility.

Standardized descriptions of TVUS images according to updated classifications are decisive for achieving individualized therapeutic approaches within the clinical context of each patient.

Magnetic resonance imaging has been also shown to be a helpful complementary imaging technique to TVUS for the assessment of women presenting with coexisting endometriosis and adenomyosis. In cases of multiple UFs (>4), a large uterus (>375 cm³), or doubts of malignancy, MRI appears to be superior to TVUS.

New techniques, which are still mainly in the research stage, may contribute to improving diagnostic accuracy in certain situations in the near future. These techniques include SIS to complement intrauterine images visualized using TVUS, and elastography and CEUS for the differential diagnosis between UFs, adenomyosis, and uterine malignancies. Finally, AI-assisted techniques may improve efficiency in the diagnosis and follow-up of UFs and may change the way UFs are diagnosed in the near future.

Acknowledgments

The authors express their gratitude to the Society of Endometriosis and Uterine Disorders (SEUD) Forum held in October 2023 (Sevilla, Spain) and also express our gratitude to the SEUD team participating in the review and to Dr. Cristina Ros for the TVUS images.

CRedit Authorship Contribution Statement

Eduard Mension: Conceptualization, Methodology, Writing – original draft; **Francisco Carmona:** Conceptualization, Writing – original draft, Validation, Visualization, Investigation, Supervision, Writing – review & editing; **Silvia Vannuccini:** Validation, Visualization, Investigation, Supervision, Writing – review & editing; **Charles Chapron:** Validation, Visualization, Investigation, Supervision, Writing – review & editing.

Declaration of Interests

E.M. has nothing to disclose. F.C. has nothing to disclose. S.V. reports honoraria for lectures from Gedeon Richter. C.C. has nothing to disclose.

REFERENCES

- Baird DD, Dunson DB, Hill MC, Cousins D, Schectman JM. High cumulative incidence of uterine leiomyoma in black and white women: ultrasound evidence. *Am J Obstet Gynecol* 2003;188:100–7.
- Pavone D, Clemenza S, Sorbi F, Fambrini M, Petraglia F. Epidemiology and risk factors of uterine fibroids. *Best Pract Res Clin Obstet Gynaecol* 2018;46:3–11.
- Dolmans MM, Petraglia F, Catherino WH, Donnez J. Pathogenesis of uterine fibroids: current understanding and future directions. *Fertil Steril* 2024;122:6–11.
- Donnez J, Taylor HS, Marcellin L, Dolmans MM. Uterine fibroid-related infertility: mechanisms and management. *Fertil Steril* 2024;122:31–9.
- Stewart E, Cookson C, Gandolfo R, Schulze-Rath R. Epidemiology of uterine fibroids: a systematic review. *BJOG Int J Obstet Gynaecol* 2017;124:1501–12.
- Reis FM, Bloise E, Ortiga-Carvalho TM. Hormones and pathogenesis of uterine fibroids. *Best Pract Res Clin Obstet Gynaecol* 2016;34:13–24.
- Ulin M, Ali M, Chaudhry ZT, Al-Hendy A, Yang Q. Uterine fibroids in menopause and perimenopause. *Menopause* 2020;27:238–42.
- Hale GE, Manconi F, Luscombe G, Fraser IS. Quantitative measurements of menstrual blood loss in ovulatory and anovulatory cycles in middle- and late-reproductive age and the menopausal transition. *Obstet Gynecol* 2010;115:249–56.
- Fuldeore MJ, Soliman AM. Patient-reported prevalence and symptomatic burden of uterine fibroids among women in the United States: findings from a cross-sectional survey analysis. *Int J Womens Health* 2017;9:403–11.
- Munro MG, Critchley HOD, Fraser IS. The FIGO classification of causes of abnormal uterine bleeding: Malcolm G. Munro, Hilary O.D. Critchley, Ian S. Fraser, for the FIGO Working Group on menstrual disorders. *Int J Gynaecol Obstet* 2011;113:1–2.
- Ni P, Wu M, Guan H, Yuan Y, Zhang L, Zhang F, et al. Etiology distribution of abnormal uterine bleeding according to FIGO classification system: a combined study of ultrasound and histopathology. *J Obstet Gynaecol Res* 2022;48:1913–20.
- Munro MG. Classification of menstrual bleeding disorders. *Rev Endocr Metab Disord* 2012;13:225–34.
- Vannuccini S, Jain V, Critchley H, Petraglia F. From menarche to menopause, heavy menstrual bleeding is the underrated compass in reproductive health. *Fertil Steril* 2022;118:625–36.
- Treloar AE, Boynton RE, Behn BG, Brown BW. Variation of the human menstrual cycle through reproductive life. *Int J Fertil* 1967;12:77–126.
- Stewart EA, Nowark RA. Leiomyoma-related bleeding: a classic hypothesis updated for the molecular era. *Hum Reprod Update* 1996;2:295–306.
- Bereza T, Lis G, Mitus J, Sporek M, Chmielewski P, Kolber W, et al. Blood vessels of the intratumoral septa in uterine leiomyomata. *Folia Med Cracov* 2013;53:99–106.
- Don EE, Middelkoop MA, Hehenkamp WJK, Mijatovic V, Griffioen AW, Huirne JAF. Endometrial angiogenesis of abnormal uterine bleeding and infertility in patients with uterine fibroids—a systematic review. *Int J Mol Sci* 2023;24:7011.
- Nelson AL, Ritchie JJ. Severe anemia from heavy menstrual bleeding requires heightened attention. *Am J Obstet Gynecol* 2015;213:97.e1–6.
- Donnez J, Carmona F, Maitrot-Mantelet L, Dolmans MM, Chapron C. Uterine disorders and iron deficiency anemia. *Fertil Steril* 2022;118:615–24.
- Zimmermann A, Bernuit D, Gerlinger C, Schaeffers M, Geppert K. Prevalence, symptoms and management of uterine fibroids: an international internet-based survey of 21,746 women. *BMC Womens Health* 2012;12:6.
- David M, Pitz CM, Mihaylova A, Siedentopf F. Myoma-associated pain frequency and intensity: a retrospective evaluation of 1548 myoma patients. *Eur J Obstet Gynecol Reprod Biol* 2016;199:137–40.
- Ferrero S, Abbamonte LH, Giordano M, Parisi M, Ragni N, Remorgida V. Uterine myomas, dyspareunia, and sexual function. *Fertil Steril* 2006;86:1504–10.
- Somigliana E, Reschini M, Bonanni V, Busnelli A, Li Piani L, Vercellini P. Fibroids and natural fertility: a systematic review and meta-analysis. *Reprod Biomed Online* 2021;43:100–10.
- Nishino M, Togashi K, Nakai A, Hayakawa K, Kanao S, Iwasaku K, et al. Uterine contractions evaluated on cine MR imaging in patients with uterine leiomyomas. *Eur J Radiol* 2005;53:142–6.

25. Orisaka M, Kurokawa T, Shukunami KI, Orisaka S, Fukuda MT, Shinagawa A, et al. A comparison of uterine peristalsis in women with normal uteri and uterine leiomyoma by cine magnetic resonance imaging. *Eur J Obstet Gynecol Reprod Biol* 2007;135:111–5.
26. Somigliana E, Vercellini P, Daguati R, Pasin R, De Giorgi O, Crosignani PG. Fibroids and female reproduction: a critical analysis of the evidence. *Hum Reprod Update* 2007;13:465–76.
27. Ikhen DE, Bulun SE. Literature review on the role of uterine fibroids in endometrial function. *Reprod Sci* 2018;25:635–43.
28. Pritts EA, Parker WH, Olive DL. Fibroids and infertility: an updated systematic review of the evidence. *Fertil Steril* 2009;91:1215–23.
29. Pritts EA. Fibroids and infertility: a systematic review of the evidence. *Obstet Gynecol Surv* 2001;56:483–91.
30. Hammoud AO, Asaad R, Berman J, Treadwell MC, Blackwell S, Diamond MP. Volume change of uterine myomas during pregnancy: do myomas really grow? *J Minim Invasive Gynecol* 2006;13:386–90.
31. Neiger R, Sonek JD, Croom CS, Ventolini G. Pregnancy-related changes in the size of uterine leiomyomas. *J Reprod Med* 2006;51:671–4.
32. Coutinho LM, Assis WA, Spagnuolo-Souza A, Reis FM. Uterine fibroids and pregnancy: how do they affect each other? *Reprod Sci* 2022;29:2145–51.
33. Vitagliano A, Noventa M, Di Spiezio Sardo A, Saccone G, Gizzo S, Borgato S, et al. Uterine fibroid size modifications during pregnancy and puerperium: evidence from the first systematic review of literature. *Arch Gynecol Obstet* 2018;297:823–35.
34. Woźniak A, Woźniak S. Ultrasonography of uterine leiomyomas. *Meno-pausal Rev* 2017;16:113–7.
35. Van Den Bosch T, Dueholm M, Leone FPG, Valentin L, Rasmussen CK, Votino A, et al. Terms, definitions and measurements to describe sonographic features of myometrium and uterine masses: a consensus opinion from the Morphological Uterus Sonographic Assessment (MUSA) group. *Ultrasound Obstet Gynecol* 2015;46:284–98.
36. Dueholm M, Lundorf E, Hansen ES, Ledertoug S, Olesen F. Accuracy of magnetic resonance imaging and transvaginal ultrasonography in the diagnosis, mapping, and measurement of uterine myomas. *Am J Obstet Gynecol* 2002;186:409–15.
37. Nieuwenhuis LL, Keizer AL, Stoelinga B, Twisk J, Hehenkamp W, Brölmann H, et al. Fibroid vascularisation assessed with three-dimensional power Doppler ultrasound is a predictor for uterine fibroid growth: a prospective cohort study. *BJOG Int J Obstet Gynaecol* 2018;125:577–84.
38. Keizer AL, Nieuwenhuis LL, Hehenkamp WJK, Twisk JWR, Brölmann HAM, Huirne JAF. Fibroid vascularisation assessed with 3D Power Doppler as predictor for fibroid related symptoms and quality of life; a pilot study. *Facts Views Vis Obgyn* 2021;13:387–94.
39. Van Den Bosch T, De Bruijn AM, De Leeuw RA, Dueholm M, Exacoustos C, Valentin L, et al. Sonographic classification and reporting system for diagnosing adenomyosis. *Ultrasound Obstet Gynecol* 2019;53:576–82.
40. Lasmar RB, Barrozo PRM, Dias R, De Oliveira MAP. Submucous myomas: a new presurgical classification to evaluate the viability of hysteroscopic surgical treatment—preliminary report. *J Minim Invasive Gynecol* 2005;12:308–11.
41. Camanni M, Bonino L, Tassarolo M, Migliaretti G, Ferrero B, Deltetto F. Is it possible to obtain a presurgical Lasmar score for hysteroscopic myomectomy by ultrasound alone? *Ultrasound Obstet Gynecol* 2012;40:106–11.
42. Lasmar RB, Xinmei Z, Indman PD, Celeste RK, Di Spiezio Sardo A. Feasibility of a new system of classification of submucous myomas: a multicenter study. *Fertil Steril* 2011;95:2073–7.
43. Testa AC, Di Legge A, Bonatti M, Manfredi R, Scambia G. Imaging techniques for evaluation of uterine myomas. *Best Pract Res Clin Obstet Gynaecol* 2016;34:37–53.
44. Nicholson TA, Pelage JP, Ettles DF. Fibroid calcification after uterine artery embolization: ultrasonographic appearance and pathology. *J Vasc Interv Radiol* 2001;12:443–6.
45. Szabó I, Szánthó A, Csabay L, Csapó Z, Szirmai K, Papp Z. Color Doppler ultrasonography in the differentiation of uterine sarcomas from uterine leiomyomas. *Eur J Gynaecol Oncol* 2002;23:29–34.
46. Testa AC, Pomini F, Fattorossi A, Battaglia A, Ferrandina G, Mansueto D, et al. Doppler velocimetry and cytofluorimetric analysis in uterine myomas. *Gynecol Invest* 2003;56:139–42.
47. Exacoustos C, Romanini ME, Amadio A, Amoroso C, Szabolcs B, Zupi E, et al. Can gray-scale and color Doppler sonography differentiate between uterine leiomyosarcoma and leiomyoma? *J Clin Ultrasound* 2007;35:449–57.
48. Sunkara SK, Khairy M, El-Toukhy T, Khalaf Y, Coomarasamy A. The effect of intramural fibroids without uterine cavity involvement on the outcome of IVF treatment: a systematic review and meta-analysis. *Hum Reprod* 2010;25:418–29.
49. Bazot M, Daraï E. Role of transvaginal sonography and magnetic resonance imaging in the diagnosis of uterine adenomyosis. *Fertil Steril* 2018;109:389–97.
50. Raffone A, Raimondo D, Neola D, Travaglino A, Giorgi M, Lazzeri L, et al. Diagnostic accuracy of MRI in the differential diagnosis between uterine leiomyomas and sarcomas: a systematic review and meta-analysis. *Int J Gynecol Obstet* 2024;165:22–33.
51. Raffone A, Raimondo D, Neola D, Travaglino A, Raspollini A, Giorgi M, et al. Diagnostic accuracy of ultrasound in the diagnosis of uterine leiomyomas and sarcomas. *J Minim Invasive Gynecol* 2024;31:28–36.e1.
52. Bonneau C, Thomassin-Naggara I, Dechoux S, Cortez A, Daraï É, Rouzier R. Value of ultrasonography and magnetic resonance imaging for the characterization of uterine mesenchymal tumors. *Acta Obstet Gynecol Scand* 2014;93:261–8.
53. Sato K, Yuasa N, Fujita M, Fukushima Y. Clinical application of diffusion-weighted imaging for preoperative differentiation between uterine leiomyoma and leiomyosarcoma. *Am J Obstet Gynecol* 2014;210:368.e1–8.
54. Kumar K, Pajai S, Baidya GR, Majhi K. Utility of saline infusion sonohysterography in gynecology: a review article. *Cureus* 2023;15:e35424.
55. Seshadri S, El-Toukhy T, Douiri A, Jayaprasakan K, Khalaf Y. Diagnostic accuracy of saline infusion sonography in the evaluation of uterine cavity abnormalities prior to assisted reproductive techniques: a systematic review and meta-analyses. *Hum Reprod Update* 2015;21:262–74.
56. Bittencourt CA, Dos Santos Simões R, Bernardo WM, Fuchs LFP, Soares Júnior JM, Pastore AR, et al. Accuracy of saline contrast sonohysterography in detection of endometrial polyps and submucosal leiomyomas in women of reproductive age with abnormal uterine bleeding: systematic review and meta-analysis. *Ultrasound Obstet Gynecol* 2017;50:32–9.
57. Grimbizis GF, Tsolakidis D, Mikos T, Anagnostou E, Asimakopoulos E, Stamatopoulos P, et al. A prospective comparison of transvaginal ultrasound, saline infusion sonohysterography, and diagnostic hysteroscopy in the evaluation of endometrial pathology. *Fertil Steril* 2010;94:2720–5.
58. Bingol B, Gunenc Z, Gedikbasi A, Guner H, Tasdemir S, Tiras B. Comparison of diagnostic accuracy of saline infusion sonohysterography, transvaginal sonography and hysteroscopy. *J Obstet Gynaecol* 2011;31:54–8.
59. Short J, Sharp B, Elliot N, McEwing R, McGeoch G, Shand B, et al. Does the addition of saline infusion sonohysterography to transvaginal ultrasonography prevent unnecessary hysteroscopy in premenopausal women with abnormal uterine bleeding? *Aust N Z J Obstet Gynaecol* 2016;56:432–5.
60. Stoelinga B, Hehenkamp WJK, Brölmann HAM, Huirne JAF. Real-time elastography for assessment of uterine disorders. *Ultrasound Obstet Gynecol* 2014;43:218–26.
61. Tassarolo M, Bonino L, Camanni M, Deltetto F. Elastasonography: a possible new tool for diagnosis of adenomyosis? *Eur Radiol* 2011;21:1546–52.
62. Pongpunprut S, Paburana P, Wibulpolprasert P, Waiyaput W, Sroyraya M, Chansoon T, et al. A comparison of shear wave elastography between normal myometrium, uterine fibroids, and adenomyosis: a cross-sectional study. *Int J Fertil Steril* 2022;16:49–54.
63. Wang XL, Lin S, Lyu GR. Advances in the clinical application of ultrasound elastography in uterine imaging. *Insights Imaging* 2022;13:141.
64. Torkzaban M, Machado P, Gupta I, Hai Y, Forsberg F. Contrast-enhanced ultrasound for monitoring non-surgical treatments of uterine fibroids: a systematic review. *Ultrasound Med Biol* 2021;47:3–18.
65. Stoelinga B, Dooper AMC, Juffermans LJM, Postema AW, Wijkstra H, Brölmann HAM, et al. Use of contrast-enhanced ultrasound in the

- assessment of uterine fibroids: a feasibility study. *Ultrasound Med Biol* 2018;44:1901–9.
66. Zhang XL, Zheng RQ, Yang YB, Huang DM, Song Q, Mao YJ, et al. The use of contrast-enhanced ultrasound in uterine leiomyomas. *Chin Med J (Engl)* 2010;123:3095–9.
67. Stoelinga B, Juffermans L, Dooper A, De Lange M, Hehenkamp W, Van Den Bosch T, et al. Contrast-enhanced ultrasound imaging of uterine disorders: a systematic review. *Ultrasound Imaging* 2021;43:239–52.
68. Chhabra P, Daugherty R, LeNoir AM, Grilli C, Makai G, Patel N, et al. Comparison of contrast-enhanced ultrasound versus magnetic resonance imaging in the detection and characterization of uterine leiomyomas. *J Ultrasound Med* 2021;40:1147–53.
69. Nishizawa S, Inubushi M, Kido A, Miyagawa M, Inoue T, Shinohara K, et al. Incidence and characteristics of uterine leiomyomas with FDG uptake. *Ann Nucl Med* 2008;22:803–10.
70. Huo T, Li L, Chen X, Wang Z, Zhang X, Liu S, et al. Artificial intelligence-aided method to detect uterine fibroids in ultrasound images: a retrospective study. *Sci Rep* 2023;13:3714.
71. Shahzad A, Mushtaq A, Sabeeh AQ, Ghadi YY, Mushtaq Z, Arif S, et al. Automated uterine fibroids detection in ultrasound images using deep convolutional neural networks. *Healthcare (Basel)* 2023;11:1493.
72. Yang T, Yuan L, Li P, Liu P. Real-time automatic assisted detection of uterine fibroid in ultrasound images using a deep learning detector. *Ultrasound Med Biol* 2023;49:1616–26.