



# Prenatal identification of invasive placentation using magnetic resonance imaging: systematic review and meta-analysis

F. D'ANTONIO\*, C. IACOVELLA\*, J. PALACIOS-JARAQUEMADA†, C. H. BRUNO‡, L. MANZOLI§¶ and A. BHIDE\*

\*Fetal Medicine Unit, Division of Developmental Sciences, St George's University of London, London, UK; †Centre for Medical Education and Clinical Research, Department of Gynecology and Obstetrics, Buenos Aires, Argentina; ‡South Scientific Foundation, MRI Department Diagnosis, Lomas de Zamora, Buenos Aires, Argentina; §Department of Medicine and Aging Sciences, University of Chieti-Pescara, Italy; ¶CeSI Biotech, Chieti, Italy

**KEYWORDS:** invasive placental implantation; MRI; placenta accreta; prenatal diagnosis

## ABSTRACT

**Objective** To assess systematically the performance of prenatal magnetic resonance imaging (MRI) in diagnosing the presence, degree and topography of disorders of invasive placentation and to explore the role of the different MRI signs in predicting these disorders. The diagnostic accuracy of ultrasound and MRI in the detection of invasive placentation was also compared.

**Methods** MEDLINE, EMBASE, CINAHL and The Cochrane Library, including The Cochrane Database of Systematic Reviews, Database of Abstracts of Reviews of Effects and The Cochrane Central Register of Controlled Trials, were searched electronically utilizing combinations of the relevant medical subject heading terms, keywords and word variants for 'invasive placentation' and 'magnetic resonance imaging'. Only prospective studies reporting a diagnosis of invasive placentation at the time of MRI and retrospective studies in which the radiologist was blinded to the final results were included in the analysis. The MRI signs explored were: uterine bulging, heterogeneous signal intensity, dark intraplacental bands on T2 weighted sequences, focal interruption of the myometrium and tenting of the bladder. Summary estimates of sensitivity, specificity, positive and negative likelihood ratios (LR+, LR-) and diagnostic odds ratio (DOR) were based, depending on the number of studies, upon DerSimonian–Laird random-effect or hierarchical summary receiver–operating characteristics models.

**Results** A total of 18 studies involving 1010 pregnancies at risk for invasive placentation were included. The overall diagnostic accuracy of MRI in detecting the presence of invasive placentation was: sensitivity, 94.4% (95% CI, 86.0–97.9%); specificity, 84.0% (95% CI, 76.0–89.8%); LR+, 5.91 (95% CI, 3.73–9.39); LR-, 0.07 (95% CI, 0.02–0.18); DOR, 89.0 (95% CI, 22.8–348.1). MRI had

a high predictive accuracy in assessing both the depth and topography of placental invasion. All five MRI signs showed good predictive accuracy in the diagnosis of disorders of invasive placentation. There was no difference in either the sensitivity ( $P=0.24$ ) or the specificity ( $P=0.91$ ) between ultrasound and MRI for the detection of invasive placentation.

**Conclusions** Prenatal MRI is highly accurate in diagnosing disorders of invasive placentation. Ultrasound and MRI have comparable predictive accuracy. Large population-based studies are needed in order to assess whether ultrasound can predict the depth and topography of placental invasion as reliably as can MRI. Copyright © 2014 ISUOG. Published by John Wiley & Sons Ltd.

## INTRODUCTION

Morbidly adherent placenta encompasses a spectrum of conditions characterized by an abnormal adherence of the placenta to the implantation site<sup>1</sup>. The importance of antenatal detection of invasive placentation relies on the fact that maternal morbidity has been shown to decrease when these disorders are diagnosed prenatally, as it allows pre-planned treatment of the condition<sup>2–4</sup>. Placenta previa and previous uterine surgery represent two major risk factors for invasive placentation, thus such pregnancies should be routinely screened for adherent placentae, especially in the third trimester of pregnancy.

Ultrasonography is usually employed as the primary modality for antenatal diagnosis of invasive placenta, while prenatal magnetic resonance imaging (MRI) is reported to be complementary to ultrasound and may help in diagnosing these disorders, especially in those conditions for which ultrasound is inconclusive, or to assess the depth and extent of invasion<sup>5,6</sup>.

Correspondence to: Dr A. Bhide, Fetal Maternal Medicine Unit, St George's University of London, London SW17 0RE, UK (e-mail: abhide@sgul.ac.uk)

Accepted: 28 January 2014

The management of disorders of placental invasion requires a multidisciplinary approach. Perioperative internal iliac artery occlusion, performed using interventional radiology techniques, reduces intraoperative blood loss and the need for transfusion during Cesarean section<sup>7,8</sup>. Similarly, an accurate knowledge of Sector 1 (uterine body), Sector 2 (lower uterine segment/cervix) and lateral (parametrial) extension of placental invasion helps in tailoring the surgical approach<sup>9</sup>. There is evidence to suggest that the incidence of disorders of invasive placentation is increasing. Although it is generally accepted that ultrasound constitutes a highly reliable tool for diagnosing disorders of invasive placentation, it is not entirely clear whether MRI improves the diagnostic accuracy of ultrasound, nor which MRI signs should be used to diagnose this condition<sup>10</sup>.

The aims of this systematic review were first, to evaluate the predictive accuracy of MRI as a test for the diagnosis of invasive placental disorders; second, to assess the predictive accuracy of MRI in assessing the depth and topography of placental invasion; and third, to compare the performance of ultrasound *vs* MRI in detecting the presence of disorders of placental invasion. The diagnostic performance of different MRI signs in predicting invasive placental disorders was also explored.

## METHODS

### Systematic review, data source and search strategy

This review was performed according to an *a priori* designed protocol recommended for systematic reviews and meta-analyses<sup>11–13</sup>. MEDLINE, EMBASE, CINAHL and The Cochrane Library, including The Cochrane Database of Systematic Reviews, Database of Abstracts of Reviews of Effects and The Cochrane Central Register of Controlled Trials, were searched electronically on 24<sup>th</sup> April 2013 and updated on 3<sup>rd</sup> September 2013, utilizing combinations of the relevant medical subject heading (MeSH) terms, keywords, and word variants for 'placenta accreta', 'placenta increta', 'placenta percreta', 'ultrasound', 'magnetic resonance imaging (MRI)' and 'invasive placenta'. The search and selection criteria were restricted to the English language. Reference lists of relevant articles and reviews were hand searched for additional reports.

### Study selection

Studies were assessed according to the following criteria: population, outcome, prenatal diagnosis of placenta accreta by MRI and study design. For the purpose of this study, invasive placentation was defined based on histopathological diagnosis of trophoblastic invasion through the myometrium or clinical assessment of abnormal adherence/evidence of gross placental invasion at the time of surgery in the absence of histopathological evidence.

For evaluation of the diagnostic performance of MRI in detecting disorders of invasive placentation, the general term 'invasive placentation' will refer to placenta accreta and its variants (increta/percreta). Only prospective

studies reporting a diagnosis of invasive placentation at the time of the examination and retrospective studies in which radiologists were blinded to the pathological/surgical diagnosis, and studies for which the values of true positive, false positive, true negative and false negative were available, were included in the analysis. In cases in which the overall performance of MRI and the number of imaging criteria used to diagnose invasive placentation were not stated, the sign showing the best predictive value was used as a surrogate for the final diagnosis.

For comparison of ultrasound with MRI, only studies in which the two imaging techniques were carried out on the same number of women, irrespective of the knowledge of the ultrasound diagnosis, were considered suitable for the analysis. A subanalysis restricted only to studies in which radiologists were blinded both to the ultrasound findings and to the final diagnosis was also performed.

The MRI signs included in this review were the ones most commonly reported to be associated with invasive placentation and comprise: uterine bulging, heterogeneous signal intensity in the placenta, dark intraplacental bands on T2 weighted sequences, focal interruption of the myometrium and tenting of the bladder<sup>14</sup>.

Prospective and retrospective cohorts, case-control studies, case reports and case series were analyzed. Opinions and studies carried out only in the first trimester of pregnancy were excluded. Case reports and case series with fewer than five cases and larger case series with a lack of information on false negatives were also excluded in order to avoid publication bias.

### Data extraction

Two reviewers (F.D. and C.I.) independently extracted data. Inconsistencies were discussed by the reviewers and consensus reached. For those articles in which targeted information was not reported but the methodology was such that the information might have been recorded initially, the authors were contacted requesting the data. Histopathological findings and/or surgical notes were used as the gold standard. Depth of invasion was categorized as no invasion, accreta, increta or percreta. Topography of placental invasion was categorized as invasion of Sector 1, Sector 2 or parametria<sup>9</sup>.

### Quality assessment

The quality of the studies was assessed using the revised tool for the quality assessment of diagnostic accuracy studies (QUADAS-2)<sup>15</sup>. Each item was scored a 'yes' or 'no', or 'unclear' if there was insufficient information to make an accurate judgment.

### Statistical analysis

Summary estimates of sensitivity, specificity, positive and negative likelihood ratios (LR + and LR-) and diagnostic odds ratio (DOR) for the overall predictive accuracy of MRI, different MRI signs and for comparison between

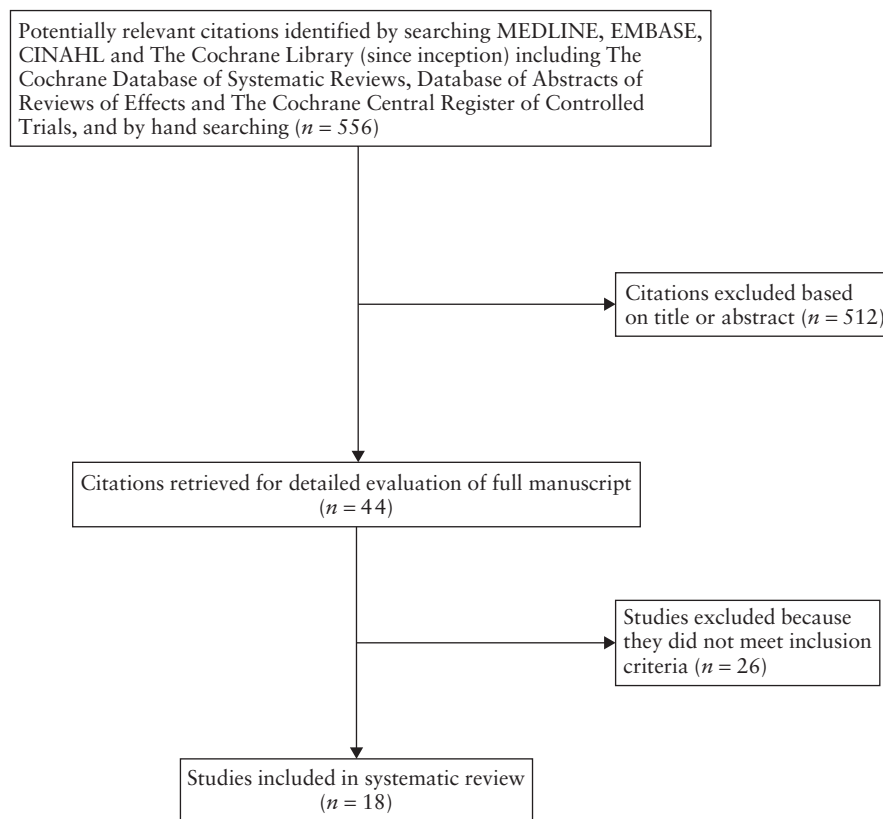


Figure 1 Flow-chart of papers considered for systematic review.

ultrasound and MRI were computed using the hierarchical summary receiver–operating characteristics (HSROC) model<sup>16</sup>. Rutter and Gatsonis HSROC parameterization was used because it models functions of sensitivity and specificity to define a summary ROC curve, and its hierarchical modeling strategy can be used for comparisons of test accuracy when there is variability in threshold between studies<sup>17</sup>. However, when the number of studies is small, the uncertainty associated with the estimation of the shape parameter could be very high, and models may fail to converge. Thus, for all meta-analyses in which fewer than four study estimates could be pooled, the DerSimonian–Laird random-effect model was used.

The DOR is defined as the ratio of the odds of the test being positive if the subject has a disease, relative to the odds of the test being positive if the subject does not have the disease, i.e.  $LR+/LR-$ <sup>18</sup>.

Potential publication bias was formally assessed through Egger's regression asymmetry test and Begg's adjusted rank correlation test. Following specific indications for meta-analyses of diagnostic accuracy, we correlated individual study sample sizes with both sensitivity and specificity as measures of test accuracy<sup>19</sup>. Only meta-analyses with more than five studies could be assessed, because both tests are unreliable when the number of primary studies is small<sup>17</sup>.

Meta-Disc 1.4 ([http://www.hrc.es/investigacion/meta\\_disc\\_en.htm](http://www.hrc.es/investigacion/meta_disc_en.htm)) and Stata command metandi (Stata Corp., College Station, TX, USA; 2013) were used to analyze the data<sup>20</sup>.

## RESULTS

### General characteristics of the studies

The search yielded 556 possible citations; of these, 512 were excluded by reviewing the title or the abstract. Of the remaining 44 full-text manuscripts that were retrieved, 26 studies were excluded because they did not meet the inclusion criteria (Table S1), thus 18 studies were finally included in the review (Figure 1). These 18 studies included 1010 pregnancies at risk for invasive placentation. A summary of the identified studies is shown in Tables 1 and S2.

Quality assessment based on QUADAS-2 guidelines was conducted on all 18 studies included for systematic review (Figure 2). Most of the studies were of high quality and there was a low risk of bias and low level of concern regarding the applicability of the studies.

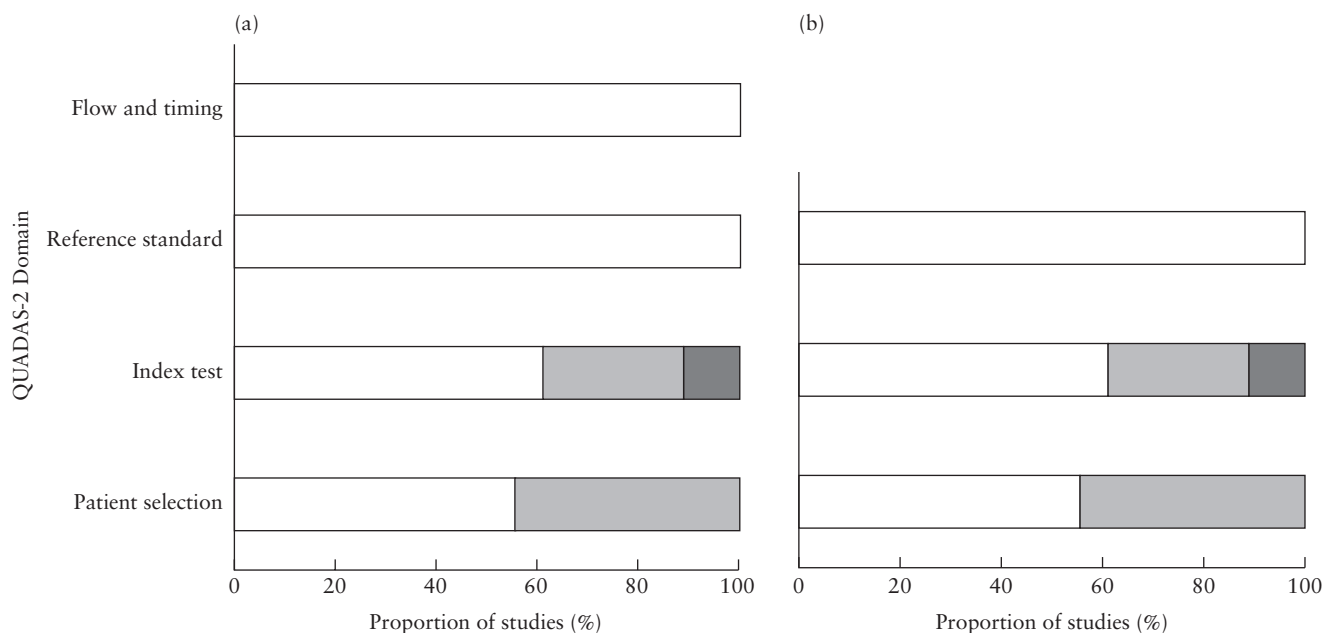
With regard to publication bias, neither Begg's nor Egger's test showed significant *P*-values for any of the outcomes considered. Although publication bias does not seem to be significant in the present meta-analysis, no method is currently validated to formally assess publication bias in meta-analyses of diagnostic tests<sup>21</sup>.

In several studies exploring the comparison between MRI and ultrasound for the detection of disorders of invasive placentation, MRI was carried out only on a proportion of pregnancies referred for ultrasound. As this was likely to affect the predictive accuracy of the test itself, we did not include such studies in the comparison

Table 1 General characteristics of studies included in systematic review

First author	Country	Study design	Inclusion criteria	GA at scan	Reference standard	Field strength	Contrast material	Pregnancies (n)	Invasive placentae (n)
Peker 2013 <sup>24</sup>	Turkey	Prosp.	Placenta previa ± previous uterine surgery	3 <sup>rd</sup> trimester	Pathology	1.5 T	No	40	20
Elhawary 2013 <sup>25</sup>	Egypt	Prosp.	Placenta previa ± advanced maternal age ± multiparity ± previous uterine surgery	3 <sup>rd</sup> trimester	Surgery	1.5 T	No	39	8
Maher 2013 <sup>29</sup>	Saudi Arabia/Egypt	Prosp.	Suspicion of invasive placentation on US	3 <sup>rd</sup> trimester	Pathology/surgery	1.5 T	No	20	7
Alamo 2013 <sup>30</sup>	Switzerland	Retro.	Suspicion of invasive placentation on US	3 <sup>rd</sup> trimester	Pathology/surgery	1.5 T	No	25	12
Palacios-Jaraquemada 2013 <sup>9*</sup>	Argentina	Retro.	Suspicion of invasive placentation clinically or on US	3 <sup>rd</sup> trimester	Surgery	1.5 T	No	572	559
Shweel 2012 <sup>31</sup>	Egypt	Retro.	Previous uterine surgery, placenta previa or low lying and suspicion of invasive placentation on US	< 30 weeks	Pathology/surgery	1.0 T	No	28	11
McLean 2011 <sup>32</sup>	USA	Retro.	US suspicion or risk factors for invasive placentation	2 <sup>nd</sup> –3 <sup>rd</sup> trimester	Surgery	1.5 T	No	40	26
Mansour 2011 <sup>23</sup>	Egypt	Prosp.	Placenta previa ± previous uterine surgery	3 <sup>rd</sup> trimester	Surgery	1.5 T	No	35	15
Lim 2011 <sup>33</sup>	USA	Retro.	Previous uterine surgery ± third trimester bleeding, uterine fibroids	2 <sup>nd</sup> –3 <sup>rd</sup> trimester	Pathology	1.5 T	No	13	9
Derman 2011 <sup>34</sup>	USA	Retro.	US suspicion of invasive placentation, inconclusive US	3 <sup>rd</sup> trimester†	Pathology/surgery	1.5 T	No	17	4
Teo 2009 <sup>35</sup>	Singapore	Retro.	Clinical or US suspicion of invasive placentation	3 <sup>rd</sup> trimester	Pathology/surgery	1.5 T	No	7	6
Masselli 2008 <sup>22</sup>	Italy	Prosp.	Placenta previa and previous CS	2 <sup>nd</sup> –3 <sup>rd</sup> trimester	Pathology/surgery	1.5 T	N/S	50	12
Dwyer 2008 <sup>36</sup>	USA	Retro.	US or clinical suspicion of invasive placentation	N/S	Pathology/clinical findings	1.5 T	No	32	15
Lax 2007 <sup>37</sup>	USA	Retro.	US or clinical suspicion of invasive placentation	3 <sup>rd</sup> trimester	Pathology/surgery	1.5 T	No	20	10
Warshack 2006 <sup>38</sup>	USA	Retro.	US suspicion of invasive placentation, inconclusive US	2 <sup>nd</sup> –3 <sup>rd</sup> trimester	Pathology	1.5 T	Yes	40	26
Kim 2004 <sup>39</sup>	USA	Retro.	Previous uterine surgery ± US suspicion of invasive placentation	3 <sup>rd</sup> trimester	Pathology/surgery	1.5 T	No	5	3
Lam 2002 <sup>40</sup>	USA	Retro.	US suspicion of invasive placentation ± previous uterine surgery ± placenta previa or low lying	2 <sup>nd</sup> –3 <sup>rd</sup> trimester	Pathology	1.5 T	Yes‡	9	5
Levine 1999 <sup>41</sup>	USA	Prosp.	Previous CS or uterine surgery ± placenta previa	3 <sup>rd</sup> trimester	Pathology/surgery/clinical findings	1.5 T	No	18	6

\*Additional data added to the original publication. †Mean gestational age at magnetic resonance imaging. ‡Not used in two patients. ±, with or without; CS, Cesarean section; GA, Gestational age; N/S, not stated; Prosp., prospective; Retro., retrospective; US, ultrasound.



**Figure 2** Studies included in review according to quality assessment of diagnostic accuracy studies (QUADAS-2) criteria: proportion of studies with low (□), high (▣) or unclear (■) risk of bias (a) or concerns regarding applicability (b).

between the two techniques. In most of the studies assessing the diagnostic performance of MRI, the radiologists were not blinded to the ultrasound findings. Although this can affect the actual diagnostic accuracy of MRI, it is less relevant in clinical practice, in which MRI scans are often read with knowledge of ultrasound findings.

## Diagnostic accuracy

### *Presence, depth and topography of placental invasion*

The overall diagnostic accuracy of MRI in diagnosing disorders of invasive placentation was as follows: sensitivity, 94.4% (95% CI, 86.0–97.9%); specificity, 84.0% (95% CI, 76.0–89.8%); LR+, 5.91 (95% CI, 3.73–9.39); LR–, 0.07 (95% CI, 0.02–0.18); DOR, 89.0 (95% CI, 22.8–348.1). MRI had a high predictive accuracy in assessing both depth and topography of placental invasion, with a sensitivity of 92.9% (95% CI, 72.8–99.5%) and 99.6% (95% CI, 98.4–100%) and a specificity of 97.6% (95% CI, 87.1–99.9%) and 95.0% (95% CI, 83.1–99.4%), respectively (Table 2, Figure 3). These results did not change even when we restricted the studies only to those in which MRI was performed in all cases with previous Cesarean section and a low anterior placenta.

### *MRI signs*

All five MRI signs analyzed in this systematic review showed good predictive accuracy in the diagnosis of disorders of invasive placentation. Focal interruption of the myometrium and the presence of dark intraplacental bands on T2 weighted sequences showed the best sensitivity, while tenting of the bladder and uterine bulging had the best specificity (Table 3).

### *MRI vs ultrasound*

MRI and ultrasound had a similar diagnostic performance in detecting the presence of disorders of invasive placentation (MRI: sensitivity, 90.2% (95% CI, 81.3–95.1%); specificity, 88.2% (95% CI, 76.7–94.4%); LR+, 7.63 (95% CI, 3.63–16.1); LR–, 0.11 (95% CI, 0.05–0.23); DOR, 68.8 (95% CI, 19.7–239.8). Ultrasound: sensitivity, 85.7% (95% CI, 77.2–91.4%); specificity, 88.6% (95% CI, 73.0–95.7%); LR+, 7.52 (95% CI, 2.92–19.4); LR–, 0.16 (95% CI, 0.10–0.27); DOR, 46.5 (95% CI, 13.4–161.0)). There were only four studies in which MRI and ultrasound were carried out on the same at-risk population and in which the radiologists reading the scans were blinded to both the ultrasound findings and the final diagnosis<sup>22–25</sup>. When stratifying the analysis only on these studies MRI showed a sensitivity of 92.9% (95% CI, 82.4–97.3%), a specificity of 93.5% (95% CI, 82.2–97.8%), LR+ of 14.22 (95% CI, 4.92–41.1), LR– of 0.08 (95% CI, 0.03–0.20) and DOR of 186.0 (95% CI, 40.0–864.5). Ultrasound showed a sensitivity of 87.8% (95% CI, 75.8–94.3%), specificity of 96.3% (95% CI, 74.4–99.6%), LR+ of 24.0 (95% CI, 2.81–205.0), LR– of 0.13 (95% CI, 0.06–0.27) and DOR of 189.2 (95% CI, 15.8–2269) (Table 2, Figure 4).

There was no significant difference in either the sensitivity ( $P=0.24$ ) or the specificity ( $P=0.91$ ) between ultrasound and MRI for the detection of invasive placentation.

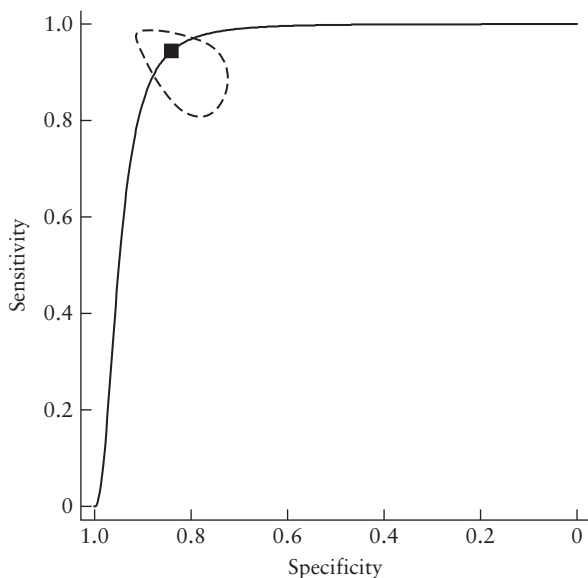
It was not possible to perform a meta-analysis for comparison of the diagnostic accuracy of ultrasound *vs* MRI in assessing the depth and topography of placental invasion because there was only one study for which the different data of diagnostic performance could be extracted<sup>22</sup>.



**Table 2** Summary estimates of sensitivity, specificity, positive and negative likelihood ratios (LR+, LR-) and diagnostic odds ratio (DOR) of magnetic resonance imaging (MRI) for detection of presence, degree and topography of placental invasion and for comparison between MRI and ultrasound (US) for detection of invasive placentation

Parameter	Studies (n)	Total sample (n)	Sensitivity (%) (95% CI)	Specificity (%) (95% CI)	DOR (95% CI)	LR+ (95% CI)	LR- (95% CI)
<b>MRI</b>							
Detection of invasive placentation	18*	1010	94.4 (86.0–97.9)	84.0 (76.0–89.8)	89.0 (22.8–348.1)	5.91 (3.73–9.39)	0.07 (0.02–0.18)
Depth of placental invasion	3†	62	92.9 (72.8–99.5)	97.6 (87.1–99.9)	44.2 (1.95–1001)	6.24 (0.43–89.7)	0.18 (0.06–0.54)
Topography of placental invasion	2†	428	99.6 (98.4–100)	95.0 (83.1–99.4)	803 (9.0–71 411)	15.8 (4.74–52.6)	0.02 (0.0–1.37)
<b>Direct comparison, MRI vs US</b>							
All studies	8*	255					
MRI			90.2 (81.3–95.1)	88.2 (76.7–94.4)	68.8 (19.7–239.8)	7.63 (3.63–16.1)	0.11 (0.05–0.23)
US			85.7 (77.2–91.4)	88.6 (73.0–95.7)	46.5 (13.4–161.0)	7.52 (2.92–19.4)	0.16 (0.10–0.27)
Only studies with blinding‡	4*	164					
MRI			92.9 (82.4–97.3)	93.5 (82.2–97.8)	186.0 (40.0–864.5)	14.22 (4.92–41.1)	0.08 (0.03–0.20)
US			87.8 (75.8–94.3)	96.3 (74.4–99.6)	189.2 (15.8–2269)	24.0 (2.81–205.0)	0.13 (0.06–0.27)

\*Computations based on hierarchical summary receiver–operating characteristics model. †Computations based on DerSimonian–Laird random-effect model. ‡Studies in which radiologist was blinded to both US findings and final diagnosis.



**Figure 3** Hierarchical summary receiver–operating characteristics (HSROC) curve of diagnostic performance of magnetic resonance imaging. Curves from HSROC model contain a summary operating point (■) representing summarized sensitivity and specificity point estimates for individual study estimates. - - - - , 95% CI.

**DISCUSSION**

The findings of this review show that prenatal MRI is highly accurate at detecting the presence, depth and topography of placental invasion. All the recorded MRI signs show an optimal diagnostic performance in identifying pregnancies with invasive placentation. MRI and ultrasound do not significantly differ in their ability to detect the presence of invasive placentation, although

the difference between the two techniques with regard to assessment of the depth and topography of placental invasion requires further evaluation.

Ultrasound represents the primary tool in evaluating women at risk for disorders of invasive placentation, while MRI is usually carried out when ultrasound is not conclusive. We report the diagnostic accuracy of MRI in detecting these disorders, but more importantly, we provide data on the diagnostic performance of MRI in assessing the depth and topography of placental invasion, especially the latter having a significant role when planning hysterectomy.

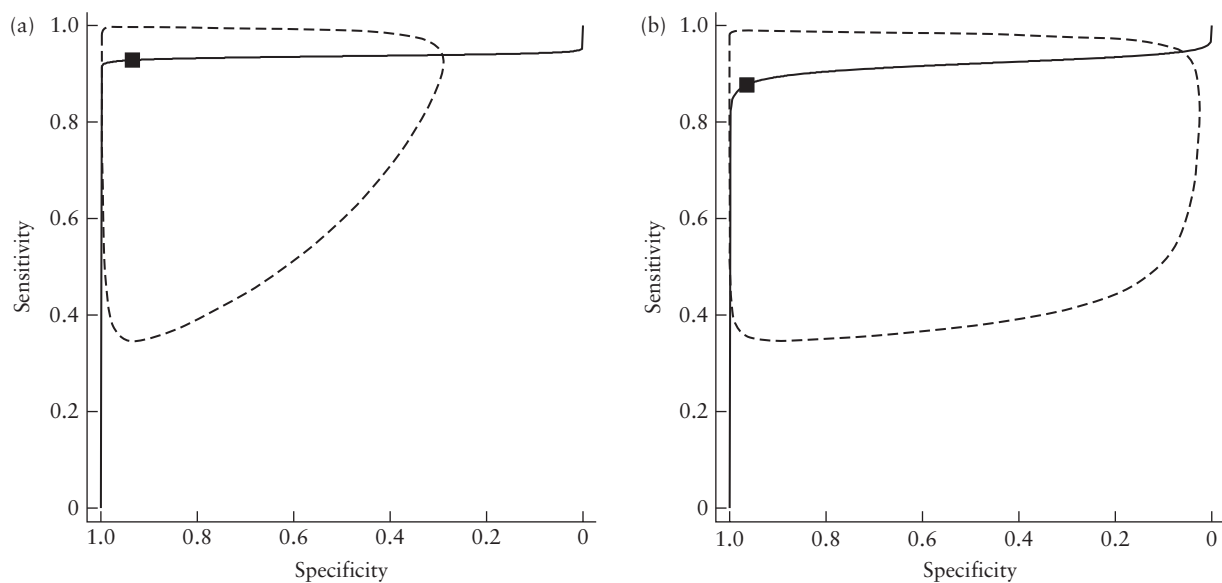
The predictive accuracy of different MRI signs is also reported. However, assessment of individual signs should be viewed with caution. In fact, observation of one sign is likely to increase the chances of detecting others, since the signs are not looked for in isolation. Finally we report that ultrasound and MRI are equally accurate in diagnosing the presence of these disorders, but the performance of ultrasound in delineating the depth and topography of placental invasion as compared with MRI needs further evaluation in the future.

The prevalence of invasive placentation in the cohort under review was nearly 75%, which suggests that this group of women was highly selected. Therefore, the diagnostic accuracy of MRI is difficult to ascertain. It might be argued that women not suspected of having an invasive placental disorder on ultrasound would not undergo MRI. Although prevalence does not influence sensitivity or specificity, the wide confidence intervals of the DOR (22.8–348) indicate the degree of uncertainty of the performance of MRI.

**Table 3** Summary estimates of sensitivity, specificity, positive and negative likelihood ratios (LR+, LR-) and diagnostic odds ratio (DOR) of different magnetic resonance imaging (MRI) signs for the detection of invasive placentation

MRI sign	Studies (n)	Total sample (n)	Sensitivity (%) (95% CI)	Specificity (%) (95% CI)	DOR (95% CI)	LR+ (95% CI)	LR- (95% CI)
Uterine bulging	5*	119	79.1 (60.3–90.4)	90.2 (76.2–96.4)	34.8 (7.46–162.4)	8.06 (2.93–22.2)	0.23 (0.11–22.2)
Heterogeneous signal intensity	6*	143	78.6 (57.7–90.8)	87.7 (50.4–98.0)	26.2 (3.85–177.8)	6.38 (1.22–33.5)	0.24 (0.12–0.52)
Dark intraplacental bands on T2-weighted MRI	6*	146	87.9 (70.9–95.6)	71.9 (55.6–84.0)	18.6 (4.12–83.8)	3.13 (1.76–5.56)	0.17 (0.06–0.48)
Focal interruption of myometrium	4*	119	92.0 (79.2–97.2)	75.6 (50.4–90.4)	35.5 (5.03–250.9)	3.77 (1.54–9.23)	0.11 (0.03–0.35)
Tenting of bladder	2†	74	80.0 (28.0–99.5)	98.6 (92.2–100)	119 (9.9–1436)	31.5 (5.9–168)	0.28 (0.07–1.09)

\*Computations based on hierarchical summary receiver–operating characteristics model. †Computations based on DerSimonian–Laird random-effect model.

**Figure 4** Hierarchical summary receiver–operating characteristics (HSROC) curves of diagnostic performance of studies comparing magnetic resonance imaging (a) and ultrasound (b). Curves from HSROC model contain a summary operating point (■) representing summarized sensitivity and specificity point estimates for individual study estimates. ---, 95% CI.

The heterogeneity in study design, populations analyzed and reference standards adopted among the different studies represents a major weakness of this meta-analysis. For example, the prevalence of invasive placentation in the study populations varied between 20% and 97%. For several meta-analyses, the number of included studies was small and some of these studies also had a small sample size. In such situations, estimates of the variances of the random effects are subject to a high level of uncertainty, and caution is required when interpreting the results. Further studies are warranted on the accuracy of MRI for assessing the depth and topography of placental invasion.

A systematic review was published recently comparing the predictive accuracy of ultrasound and MRI in detecting disorders of invasive placentation<sup>26</sup>. In this review the authors included 13 studies and reported a sensitivity of 83% (95% CI, 77–88%) and a specificity of 95% (95% CI, 93–96%), with a DOR of 63.41 (95% CI, 29.04–138.48) for ultrasound and a sensitivity of 82%

(95% CI, 72–90%) and a specificity of 88% (95% CI, 81–94%), with a DOR of 22.95 (95% CI, 3.19–165.11) for MRI. The authors did not find a significant difference between the summary ROC curves of ultrasound and those of MRI, and concluded that the diagnostic accuracy of the two techniques is similar.

A comparison of the diagnostic performance of ultrasound and MRI would require the use of MRI as a primary tool on a population at risk, or alternatively, that MRI scans are examined without knowledge of the ultrasound and pathological/surgical findings. Furthermore, the two techniques should be applied to the same population. In several studies, MRI was carried out only on a proportion of the population screened by ultrasound. This finding is likely to introduce a bias when calculating the diagnostic performance of a test. Knowledge of a positive ultrasound report might discourage a radiologist to label an MRI scan as negative, thus potentially reducing the specificity of the technique. The authors compared the

predictive accuracy of ultrasound and MRI by including all the studies in which MRI and ultrasound were carried out irrespective of the population analyzed in each study. Furthermore, they did not consider whether MRI scans were read without the knowledge of ultrasound and pathological/surgical findings.

In the current systematic review, we explore the diagnostic performance of MRI in assessing the depth and topography of placental invasion. This highlights the fact that although ultrasound is accurate for diagnosing the presence of invasive placentation, only MRI can delineate its topography, which is particularly important when hysterectomy is planned. Furthermore, we provide data on the diagnostic performance of the most commonly used MRI signs.

Ultrasound is usually employed as the primary tool in screening patients at risk for disorders of invasive placentation and it has been shown to have a high predictive accuracy. However, further assessment may be required in order to plan the surgical approach and to counsel women about the risk of potential morbidities occurring during surgery, once invasive placenta is suspected on ultrasound and a resection procedure is planned.

Although pathological classification of the degree of placental invasion is commonly used for defining disorders of invasive placentation, it may be less important when planning surgery. For example, the difference between accreta and increta is irrelevant in practice. Ultrasound has recently been shown to provide an accurate detection of the depth of placental invasion, but there are no large studies exploring its role in assessing the topography of invasion<sup>27,28</sup>. Knowledge of the lateral extent of placental invasion may help surgeons in tailoring the management by providing information about potential technical difficulties at operation, such as the need for specific hemostatic methods and to avoid damage to the ureters<sup>5</sup>. MRI has been reported to reliably provide information about parametrial invasion and uterine vascular areas. However, lateral (parametrial) extension appears to be uncommon, being reported in 16% in this series.

It is possible to predict the performance of MRI for the detection of invasive placentation in a group with a lower prevalence. We have previously argued that the most likely prevalence of invasive placentation in women with a history of previous Cesarean section and a low anterior placenta is about 20%. In that group, using the sensitivity and specificity reported in this meta-analysis, the positive predictive value and false-negative rate of MRI are likely to be 60% and 1.7%, respectively.

We have previously reported that ultrasound can reliably diagnose disorders of invasive placentation<sup>10</sup>. However, most of the studies included in that and the current systematic review showed a high heterogeneity in the diagnostic performance of these two techniques. This was most probably due to variations in the populations analyzed, experience of the operators, number of imaging signs used to label an examination as positive and choice of reference standard.

Future studies to assess the real accuracy of MRI and ultrasound in diagnosing disorders of invasive placentation should be planned in a large well-defined population. One such group is women with low anterior placenta with previous Cesarean section for whom both MRI and ultrasound are performed prospectively and reported independently of each other. Furthermore, the predictive accuracy of the commonly adopted and newly described MRI signs should be tested in the same population in order to ascertain which imaging criteria, alone or in combination, can more reliably diagnose these disorders<sup>42</sup>.

In conclusion, prenatal MRI is highly accurate in diagnosing disorders of invasive placentation, and all the commonly reported signs show an overall good predictive accuracy in the detection of these disorders. Although there is no difference between ultrasound and MRI in diagnosing these conditions, MRI should be considered in order to assess the depth and topography of placental invasion if hysterectomy is planned and lateral invasion is suspected at ultrasound. This can help in tailoring the surgical approach and in predicting perioperative complications. Large population-based studies are needed in order to assess whether ultrasound can reliably predict the depth and topography of placental invasion as accurately as can MRI.

## ACKNOWLEDGMENTS

We would like to thank Ms Tiffany Hoare and Ms Karen John-Pierre, NHS liaison librarians, St George's University of London, for their help with the literature search. We would also like to thank Dr P. Lim, Dr L. Alamo, Dr S. M. Mansour, Dr G. Lam, Dr M. Heilbrun, Prof. T. M. Elhawary and Prof. R. Resnik for their contributions to this systematic review in terms of additional data supplied and support.

## REFERENCES

- Oyelese Y, Smulian JC. Placenta previa, placenta accreta, and vasa previa. *Obstet Gynecol* 2006; **107**: 927–941.
- Tikkanen M, Paaavonen J, Loukovaara M, Stefanovic V. Antenatal diagnosis of placenta accreta leads to reduced blood loss. *Acta Obstet Gynecol Scand* 2011; **90**: 1140–1146.
- Eller AG, Porter TF, Soisson P, Silver RM. Optimal management strategies for placenta accreta. *BJOG* 2009; **116**: 648–654.
- Warshak CR, Ramos GA, Eskander R, Benirschke K, Saenz CC, Kelly TF, Moore TR, Resnik R. Effect of predelivery diagnosis in 99 consecutive cases of placenta accreta. *Obstet Gynecol* 2010; **115**: 65–69.
- Palacios-Jaraquemada JM. Efficacy of surgical techniques to control obstetric hemorrhage: analysis of 539 cases. *Acta Obstet Gynecol Scand* 2011; **90**: 1036–1042.
- Comstock CH. Antenatal diagnosis of placenta accreta: a review. *Ultrasound Obstet Gynecol* 2005; **26**: 89–96.
- Carnevale FC, Kondo MM, de Oliveira Sousa W Jr, Santos AB, da Motta Leal Filho JM, Moreira AM, Baroni RH, Francisco RP, Zugaib M. Perioperative temporary occlusion of the internal iliac arteries as prophylaxis in cesarean section at risk of hemorrhage in placenta accreta. *Cardiovasc Intervent Radiol* 2011; **34**: 758–764.
- Tan CH, Tay KH, Sheah K, Kwek K, Wong K, Tan HK, Tan BS. Perioperative endovascular internal iliac artery occlusion



- balloon placement in management of placenta accreta. *AJR Am J Roentgenol* 2007; **189**: 1158–1163.
9. Palacios-Jaraquemada JM, Bruno CH, Martín E. MRI in the diagnosis and surgical management of abnormal placentation. *Acta Obstet Gynecol Scand* 2013; **92**: 392–397.
  10. D'Antonio F, Iacovella C, Bhide A. Prenatal identification of invasive placentation using ultrasound: systematic review and meta-analysis. *Ultrasound Obstet Gynecol* 2013; **42**: 509–517.
  11. Henderson LK, Craig JC, Willis NS, Tovey D, Webster AC. How to write a Cochrane systematic review. *Nephrology (Carlton)* 2010; **15**: 617–624.
  12. NHS Centre for Reviews and Dissemination. *Systematic reviews: CRD's guidance for undertaking reviews in health care*. CRD, University of York: York, UK, 2009.
  13. Leeflang MM, Deeks JJ, Gatsonis C, Bossuyt PM; Cochrane Diagnostic Test Accuracy Working Group. Systematic reviews of diagnostic test accuracy. *Ann Intern Med* 2008; **149**: 889–897.
  14. Baughman WC, Corteville JE, Shah RR. Placenta accreta: spectrum of US and MR imaging findings. *Radiographics* 2008; **28**: 1905–1916.
  15. Whiting PF, Rutjes AW, Westwood ME, Mallett S, Deeks JJ, Reitsma JB, Leeflang MM, Sterne JA, Bossuyt PM; QUADAS-2 Group. QUADAS-2: a revised tool for the quality assessment of diagnostic accuracy studies. *Ann Intern Med* 2011; **155**: 529–536.
  16. Rutter CM, Gatsonis CA. A hierarchical regression approach to meta-analysis of diagnostic test accuracy evaluations. *Stat Med* 2001; **20**: 2865–2884.
  17. Cochrane Handbook for Systematic Reviews of Diagnostic Test Accuracy, Chapter 10; <http://srdta.cochrane.org/handbook-dta-reviews>.
  18. Glas AS, Lijmer JG, Prins MH, Bonsel GJ, Bossuyt PM. The diagnostic odds ratio: a single indicator of test performance. *J Clin Epidemiol* 2003; **56**: 1129–1135.
  19. Song F, Khan KS, Dinnes J, Sutton AJ. Asymmetric funnel plots and publication bias in meta-analyses of diagnostic accuracy. *Int J Epidemiol* 2002; **31**: 88–95.
  20. Zamora J, Abraira V, Muriel A, Khan K, Coomarasamy A. Meta-DiSc: a software for meta-analysis of test accuracy data. *BMC Med Res Methodol* 2006; **6**: 31.
  21. Leeflang MM, Deeks JJ, Takwoingi Y, Macaskill P. Cochrane diagnostic test accuracy reviews. *Syst Rev* 2013; **2**: 82.
  22. Masselli G, Brunelli R, Casciani E, Poletti E, Piccioni MG, Anceschi M, Gualdi G. Magnetic resonance imaging in the evaluation of placental adhesive disorders: correlation with color Doppler ultrasound. *Eur Radiol* 2008; **18**: 1292–1299.
  23. Mansour SM, Elkhyat WM. Placenta previa – accreta: Do we need MR imaging? *Egypt J Radiol Nucl Med* 2011; **42**: 433–442.
  24. Peker N, Turan V, Ergenoglu M, Yenieli O, Sever A, Kazandi M, Zekioglu O. Assessment of total placenta previa by magnetic resonance imaging and ultrasonography to detect placenta accreta and its variants. *Ginekol Pol* 2013; **84**: 186–192.
  25. Elhawary TM, Dabees NL, Youssef MA. Diagnostic value of ultrasonography and magnetic resonance imaging in pregnant women at risk for placenta accreta. *J Matern Fetal Neonatal Med* 2013; **26**: 1443–1449.
  26. Meng X, Xie L, Song W. Comparing the diagnostic value of ultrasound and magnetic resonance imaging for placenta accreta: a systematic review and meta-analysis. *Ultrasound Med Biol* 2013; **39**: 1958–1965.
  27. Cali G, Giambanco L, Puccio G, Forlani F. Morbidly adherent placenta: evaluation of ultrasound diagnostic criteria and differentiation of placenta accreta from percreta. *Ultrasound Obstet Gynecol* 2013; **41**: 406–412.
  28. Chalubinski KM, Pils S, Klein K, Seemann R, Speiser P, Langer M, Ott J. Prenatal sonography can predict degree of placental invasion. *Ultrasound Obstet Gynecol* 2013; **42**: 518–524.
  29. Maher MA, Abdelaziz A, Bazeed MF. Diagnostic accuracy of ultrasound and MRI in the prenatal diagnosis of placenta accreta. *Acta Obstet Gynecol Scand* 2013; **92**: 1017–1022.
  30. Alamo L, Anaye A, Rey J, Denys A, Bongartz G, Terraz S, Artemisia S, Meuli R, Schmidt S. Detection of suspected placental invasion by MRI: do the results depend on observer's experience? *Eur J Radiol* 2013; **82**: e51–e57.
  31. Shweel MAG, El Ameen NF, Ibrahim MA, Kotib A. Placenta accreta in women with prior uterine surgery: Diagnostic accuracy of Doppler ultrasonography and MRI. *Egypt J Radiol Nucl Med* 2012; **43**: 473–480.
  32. McLean LA, Heilbrun ME, Eller AG, Kennedy AM, Woodward PJ. Assessing the role of magnetic resonance imaging in the management of gravid patients at risk for placenta accreta. *Acad Radiol* 2011; **18**: 1175–1180.
  33. Lim PS, Greenberg M, Edelson MI, Bell KA, Edmonds PR, Mackey AM. Utility of ultrasound and MRI in prenatal diagnosis of placenta accreta: a pilot study. *AJR Am J Roentgenol* 2011; **197**: 1506–1513.
  34. Derman AY, Nikac V, Haberman S, Zelenko N, Opsha O, Flyer M. MRI of placenta accreta: a new imaging perspective. *AJR Am J Roentgenol* 2011; **197**: 1514–1521.
  35. Teo TH, Law YM, Tay KH, Tan BS, Cheah FK. Use of magnetic resonance imaging in evaluation of placental invasion. *Clin Radiol* 2009; **64**: 511–516.
  36. Dwyer BK, Belogolovkin V, Tran L, Rao A, Carroll I, Barth R, Chitkara U. Prenatal diagnosis of placenta accreta: sonography or magnetic resonance imaging? *J Ultrasound Med* 2008; **27**: 1275–1281.
  37. Lax A, Prince MR, Mennitt KW, Schwebach JR, Budorick NE. The value of specific MRI features in the evaluation of suspected placental invasion. *Magn Reson Imaging* 2007; **25**: 87–93.
  38. Warshak CR, Eskander R, Hull AD, Scioscia AL, Mattrey RF, Benirschke K, Resnik R. Accuracy of ultrasonography and magnetic resonance imaging in the diagnosis of placenta accreta. *Obstet Gynecol* 2006; **108**: 573–581.
  39. Kim JA, Narra VR. Magnetic resonance imaging with true fast imaging with steady-state precession and half-Fourier acquisition single-shot turbo spin-echo sequences in cases of suspected placenta accreta. *Acta Radiol* 2004; **45**: 692–698.
  40. Lam G, Kuller J, McMahan M. Use of magnetic resonance imaging and ultrasound in the antenatal diagnosis of placenta accreta. *J Soc Gynecol Invest* 2002; **9**: 37–40.
  41. Levine AB, Kuhlman K, Bonn J. Placenta accreta: comparison of cases managed with and without pelvic artery balloon catheters. *J Matern Fetal Med* 1999; **8**: 173–176.
  42. Ueno Y, Kitajima K, Kawakami F, Maeda T, Suenaga Y, Takahashi S, Matsuoka S, Tanimura K, Yamada H, Ohno Y, Sugimura K. Novel MRI finding for diagnosis of invasive placenta praevia: evaluation of findings for 65 patients using clinical and histopathological correlations. *Eur Radiol* 2014; **24**: 881–888.

## SUPPORTING INFORMATION ON THE INTERNET

The following supporting information may be found in the online version of this article:



Table S1 Excluded studies

Table S2 Magnetic resonance imaging technical characteristics of the included studies